

## Large Pyogenic Granuloma of the Maxilla in Elderly Females: Report of 2 Cases

Dr. Nanda Pai<sup>1</sup>, Dr. Zeba Sayed<sup>2</sup>, Dr. Kanan Bobda<sup>3</sup>, Dr. Raijv Desai<sup>4</sup>

<sup>1</sup>(Department of Dentistry, Seth G.S. Medical College & K.E.M. Hospital, M.U.H.S., India)

<sup>2</sup>(Department of Dentistry, Seth G.S. Medical College & K.E.M. Hospital, M.U.H.S., India)

<sup>3</sup>(Department of Dentistry, Seth G.S. Medical College & K.E.M. Hospital, M.U.H.S., India)

<sup>4</sup>(Department of Dentistry, Nair Hospital Dental College, M.U.H.S., India)

**Abstract:** Pyogenic granuloma is one of the reactive inflammatory hyperplasia commonly seen in the oral cavity. They are common in the oral cavity due to frequency with which the oral tissues are injured. It is usually in response to stimuli such as local irritation, local trauma or hormonal factors. It is seen primarily in younger pregnant females, due to vascular effects of female hormones. In this article we present two cases of unusually large pyogenic granulomas in elderly females over 70 years of age hailing from remote villages of Northern India. These lesions could have been easily detected and treated earlier, if these patients had access to proper primary healthcare. Through this article we wish to stress the need for improvement in oral healthcare awareness and emphasise the need to strengthen oral healthcare in rural India.

**Keywords:** pyogenic granuloma, pregnancy tumour, reactive inflammatory hyperplasia

### I. Introduction

Pyogenic granuloma is a common non-malignant growth of the oral cavity, first described by Hüllihen in 1844<sup>1</sup>. The term pyogenic granuloma or granuloma pyogenicum was first coined by Hartzell in 1904<sup>2</sup>. There are two types of pyogenic granuloma's – 1) Lobular Capillary Hemangioma (LCH) & 2) Non-LCH, which differ in their

histological features.

The main causes of Pyogenic granuloma are 1) Chronic low grade local irritation, 2) Trauma (local)<sup>5</sup>, 3) Hormones (especially in pregnant females), 4) Certain drugs. However, the term 'Pyogenic granuloma' is a misnomer as there is no pus or granulomatous tissue in the lesion. Trauma and poor oral hygiene could be the precipitating factors for these lesions<sup>3</sup>. Some drugs like cyclosporine have been reported to induce pyogenic granuloma like lesions<sup>4</sup>.

They are predominantly seen in second decade of life especially in young females mainly due to the effect of female hormones. About 75% of tumours seen in gingiva were caused by calculus and foreign material within the gingival crevice. Other common sites are lips, tongue and buccal mucosa<sup>5</sup>.

They may range in size from few millimetres to several centimetres, growing slowly, usually painless and colour ranging from pink, red to purple depending on age of lesion. The younger tumours are reddish in colour with considerable bleeding on minor provocation. The older lesions are more collagenized and pink<sup>6</sup>.

### II. Case History

#### 2.1 Case 1 (Fig.1)

A 70 year old female from Uttar Pradesh reported to the department of Dentistry complaining of a large mass on the right side of Maxilla since the last seven months. The lesions were painless, interfered with mastication and would bleed profusely especially on provocation. It was small initially gradually attaining the present size. The unusually large size of the lesion made the patient extremely apprehensive as to the malignant nature of the lesion.

On clinical examination there was an exophytic mass extending from the right canine to second molar in the maxilla. It was about six cm by four cm, reddish purple in colour, irregular surface and pedunculated. Patient was partially edentulous with oral hygiene extremely poor. The teeth around the lesion were mobile and covered with calculus. No cervical lymphadenopathy was noted.

Incisional biopsy was planned to rule out malignancy and help in diagnosis and management of the tumour. Tissue was taken from four different sides. The lesion was characterised by a vast number of endothelium lined vascular spaces infiltrated with lymphocytes, plasma cells, and neutrophils. There was extensive fibroblastic proliferation with a diffuse often chronic inflammatory infiltrate. The lesion was covered by a thin layer of stratified squamous epithelium.

A complete excision of the lesion was planned under General Anaesthesia. After all routine investigations this patient was taken up for surgery. The pedunculated base was first ligated using 3-0 Mersilk to

achieve pre-operative hemostasis, lesion was then excised from the base. Bleeding was controlled with electro cautery. Sharp bony margins were trimmed and primary closure achieved with electro cautery. All the mobile and periodontally affected teeth were extracted.

Postoperative healing was uneventful. Patients followed up over 6 months with no recurrence.

## 2.2 Case 2 (Fig.2)

A 70 year old female from Uttar Pradesh reported to the department of dentistry complaining of growth in anterior region of maxilla since the last one year. Although this mass was painless it caused her difficulty in incising and eating food. On examination the growth was five cm by four cm extending from canine to canine, smooth surface, pinkish in colour. No bleeding was noted. The teeth below the lesion were extracted four years ago. The lesion was sessile. No cervical lymphadenopathy was noted. Oral hygiene was fair.

An excisional biopsy was planned for this patient under general anaesthesia. After all routine investigations patient was taken up for surgery. Two percent lignocaine with adrenaline 1: 100000 was infiltrated around the lesion. It was excised from the base. It seemed attached to the incisive papilla region. The underlying bone was trimmed and wound closed using 3-0 vicryl.

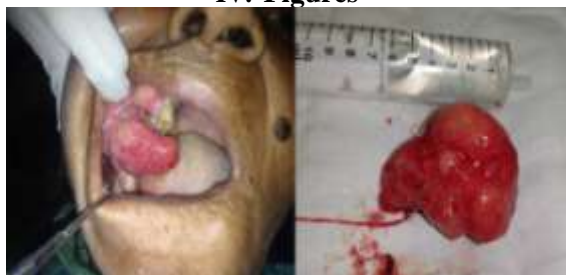Post-operative recovery was uneventful.

Histopathology report was pyogenic granuloma. Patient was followed up for 18 months.

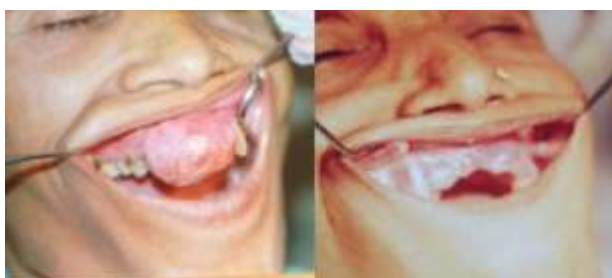### III. Histopathology

The histopathological examination (Fig.3) revealed granulation tissue with non-neoplastic proliferation of endothelial cells formation and infiltration of acute and chronic inflammatory cells in a collagenous matrix. Surface of the lesion was consistent with hyperplastic parakeratinised stratified squamous epithelium with areas of atrophy and ulcer and fibrinoleukocytic membrane. These findings were consistent with a histopathological diagnosis of pyogenic granuloma.

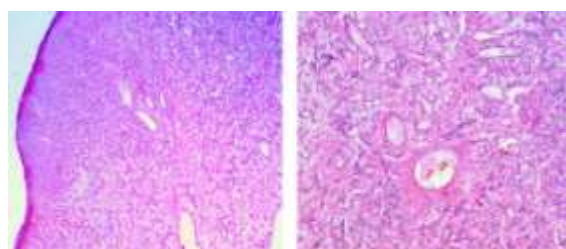
### IV. Figures



**Fig.1:** preoperative view / lesion removed in toto



**Fig.2:** preoperative front view / postoperative follow up



**Fig.3:** Photomicrograph showing atrophic, parakeratinized stratified squamous epithelium and connective tissue with numerous proliferating capillaries, dense mixed inflammatory infiltrate, and extravasated red blood cells (H & E stain, x25) / Photomicrograph showing lobular pattern of vascular proliferation with inflammation and edema resembling granulation tissue (H & E stain, x40)

## V. Discussion

About five percent pyogenic granuloma of the gingiva are associated with pregnancy hence they are also termed as pregnancy tumour or granuloma gravidarium. Bacterial plaque leads to gingivitis and this is heightened by the influence of hormonal conditions during pregnancy which can lead to gingival hyperplasia and pyogenic granuloma <sup>7</sup>.

Estrogen enhances vascular endothelial growth factor (VEGF) production in macrophages an effect antagonised by androgen and this may be the cause of pyogenic granuloma during pregnancy <sup>8</sup>.

However both our cases were in the seventh decade of life after menopause and the cause could only be attributed to local factors and poor oral hygiene.

This tumour has to be differentiated from various other lesions like peripheral giant cell granuloma, peripheral ossifying fibroma, non-Hodgkin's lymphoma, etc. and biopsy plays an important role in accurate diagnosis <sup>9</sup>.

Various treatment modalities like cryosurgery, Nd:Yag, flash lamp pulsed dye laser, injection of ethanol, or corticosteroid and sodium tetradecyl sulphate sclerotherapy have been attempted<sup>[VII]</sup>. We feel excision of the lesion with removal of local causes of irritation like calculus, or infected teeth and removal of source of trauma seem to be the effective way of managing these tumours. Lesions may recur especially if red during pregnancy, hence close follow up is mandatory for these patients.

## VI. Conclusion

To conclude pyogenic granuloma may occur as late as seventh decade of life with mobile, periodontally affected teeth as the causative factor, attaining large proportions simply because of lack of awareness and inaccessibility of primary health care.

## References

- [1]. Hullihen SP (1884) case of aneurism by anastomosis of the superior maxillae. *Am J Dent Sc* 4, 160-162.
- [2]. Hatzwell MB (1904) granuloma pyogenicum. *J Cutan Dis. Syph* 22, 520-525
- [3]. Jafarzadeh H, Sanatkhani M, Mohtasham N. Oral pyogenic granuloma: a review. *J Oral Sci.* 2006;48:167-75. [PubMed]
- [4]. Lee L, Miller PA, Maxymiw WG, Messener HA, Rotstein LE (1994) Intraoral pyogenic granuloma after allogeneic bone marrow transplant. Report of three cases. *Oral Surg and Oral Med Oral Pathol* 78, 607-610
- [5]. Sternberg SS, Antoli DA, Carter D, Millis SE, Oberman H. (1999) *Diagnostic surgical Pathology*. 3rd Ed, Lipincott Williams & Wilkins, Philadelphia. 69, 174.
- [6]. Neville BW, Damm DD, Allen CM, Bouquot JE. *Oral and Maxillofacial Surgery*. 2nd ed. Philadelphia: Saunders; 2002. p. 447-9.
- [7]. Sills ES, Zegarelli DJ, Hoschander MM, Strider WE (1996) Clinical diagnosis and management of hormonally responsive oral pregnancy tumour (pyogenic granuloma). *J Reprod Med* 41, 467-470
- [8]. Kanda N, Watanabe S (2005) Regulatory roles of sex hormones in cutaneous biology and immunology, *J Dermatol Sci* 38, 1-7
- [9]. Regezi JA, Sciubba JJ, Jordan RC. *Oral Pathology: Clinical Pathological Considerations*. 4th ed. Philadelphia: WB Saunders; 2003. p. 115-6.